

Congenital Nasal Pyriform Aperture Stenosis: Diagnosis and Treatment

Albert Losken, M.D., Fernando D. Burstein, M.D., and J. Kerwin Williams, M.D.

Atlanta, Ga.

Congenital nasal pyriform aperture stenosis is an unusual form of nasal airway obstruction in the neonate. Pediatric plastic surgeons are often involved in the management of these children and should recognize this condition and know the treatment options. Fifteen cases of children with congenital nasal pyriform aperture stenosis were reviewed for presentation of the disorder, management, and effectiveness of treatment, making it the largest series to date. There were nine male patients and six female patients in the series. They all experienced varying degrees of nasal obstruction at birth and were managed on the basis of the severity of their symptoms. Twelve patients were treated surgically in the first year of life, with a mean age at operation of 97 days (range, 3 to 362 days). Two patients required surgical intervention during their teenage years (age, 14 and 18 years) because of persistent symptoms, and one patient (age, 2 years) with mild symptoms was managed medically. Associated craniofacial anomalies were present in six cases (40 percent). Surgical enlargement of the pyriform aperture was successfully performed through an upper buccal sulcus incision in 14 patients. Preoperative symptoms of upper airway obstruction were improved in all patients at an average follow-up of 2.4 years (range, 1 month to 5 years). Congenital nasal pyriform aperture stenosis varies in presentation and severity, occurring either as an isolated congenital anomaly or in association with developmental craniofacial anomalies. It can be effectively managed by surgical enlargement of the pyriform aperture without significant recurrence or long-term morbidity. (*Plast. Reconstr. Surg.* 109: 1506, 2002.)

Nasal airway obstruction is a potentially life-threatening condition in the newborn because of obligate nasal breathing. The pyriform aperture is the narrowest, most anterior bony portion of the nasal airway, and a decrease in its cross-sectional area will significantly increase nasal airway resistance. Congenital nasal pyriform aperture stenosis is an unusual form of nasal obstruction and is not unique to the craniofacial population. It should be consid-

ered in the differential diagnosis of any neonate or infant presenting with signs and symptoms of upper airway compromise.^{1,2} It is important to differentiate this level of obstruction from the more common posterior choanal stenosis or atresia. Craniofacial surgeons are often involved in the management of children with upper airway obstruction and should be able to recognize this condition and know the treatment options. Congenital nasal pyriform aperture stenosis presents with symptoms of nasal airway obstruction often characterized by episodic apnea and cyclical cyanosis. The diagnosis is suggested by history and physical examination; however, it should be confirmed radiographically by a computed tomographic scan of the nasal cavity (Fig. 1). Numerous questions remain regarding the exact cause and degree of association with other craniofacial developmental anomalies.

In 1995, Burstein and Cohen¹ described the initial experience of four patients with nearly complete pyriform aperture stenosis. The purpose of our report is to expand this series, specifically in the areas of presentation, associated anomalies, and management strategies.

PATIENTS AND METHODS

Patients

A retrospective review was performed of 15 cases of children diagnosed with congenital nasal pyriform aperture stenosis who were seen between January 1992 and December 2000 by the craniofacial team at Children's Healthcare of Atlanta at Scottish Rite Hospital. The series consisted of nine boys and six girls. Five patients were born prematurely. Discharge data-

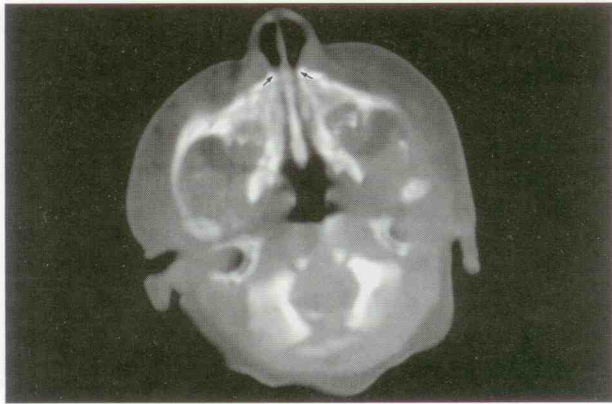


FIG. 1. Computed axial tomographic image taken at the level of the lower nasal cavity, demonstrating focal stenosis of the nasal pyriform aperture (black arrows) by the nasal process of the maxilla.

bases, medical charts, and office notes were used to analyze details of their diagnosis, preoperative assessment, initial management, surgical operations, and outcome. The degree of presentation was reviewed and the various treatment options were evaluated. Special attention was directed toward any associated physical or developmental anomalies. Postoperative courses were reviewed with particular focus on symptomatic recurrence and developmental abnormalities.

Clinical presentation represented a spectrum of severity, with varying degrees of stridor, congestion, snorting, and intermittent episodes of apnea. All patients in the series were symptomatic at birth. Symptoms were often more pronounced with feeding or with infec-

tions of the upper respiratory tract and were relieved by crying. Actual cyanotic episodes with desaturations were present in 47 percent of the patients ($n = 7$), as documented by sleep studies or continuous pulse oximetry. The inability to pass a feeding catheter through the anterior naris was occasionally experienced on physical examination, further suggesting the diagnosis of congenital nasal pyriform aperture stenosis. A controlled airway was established with endotracheal intubation or oropharyngeal tubes when necessary. The diagnosis was suspected clinically by the previously mentioned presentations and confirmed radiographically with a computed tomographic scan of the nasal cavity and maxilla (Fig. 1). Occasionally, the diagnosis was established by using nasal endoscopy.

Treatment was either medical ($n = 1$) or surgical ($n = 14$), depending on severity of the symptoms. Eighty percent of the children ($n = 12$) were treated surgically in the first year of life, with six of these treated before 1 week of age (Table I). Their mean age at operation was 97 days (range, 3 to 362 days). Two patients were managed conservatively, at first, and required surgical intervention during their teenage years (age, 14 and 18 years) because of persistent symptoms. Along with enlargement of their pyriform aperture, these adolescents also underwent an inferior turbinectomy and septoplasty. One patient (age, 2 years) was diagnosed with congenital nasal pyriform aperture stenosis at birth and has been followed medically.

TABLE I
Profile of Patients with Congenital Nasal Pyriform Aperture Stenosis Showing Management and Associated Anomalies

| Case No. | Additional Diagnosis | Age at Surgery | Management | Associated Craniofacial Anomalies | Outcome |
|----------|----------------------|----------------|--------------------------------|-----------------------------------|---------------------|
| 1 | CA | 3 days | PAE, CA repair | Apert syndrome | No recurrence |
| 2 | CA | 28 days | PAE, CA repair | Crouzon's | No recurrence |
| 3 | CA | 300 days | PAE, CA repair | Achondroplasia, MF hypoplasia | Early recurrence |
| 4 | | 89 days | PAE | Hydrocephaly | No recurrence |
| 5 | | 14 years | PAE, septoplasty, turbinectomy | Narrow vertical MF, SCMI | No recurrence |
| 6 | | 18 years | PAE, septoplasty, turbinectomy | MF hypoplasia | No recurrence |
| 7 | | 9 days | PAE | None | No recurrence |
| 8 | | 362 days | PAE | None | No recurrence |
| 9 | | 360 days | PAE | None | No recurrence |
| 10 | | 6 days | PAE | None | No recurrence |
| 11 | | 3 days | PAE | None | No recurrence |
| 12 | | 4 days | PAE | None | No recurrence |
| 13 | | 4 days | PAE | None | No recurrence |
| 14 | | 5 days | PAE | None | No recurrence |
| 15 | | N/A | Medical management | None | Occasional snorting |

CA, choanal atresia; PAE, pyriform aperture expansion; MF, midface; SCMI, single central maxillary incisor.

Surgical Technique

Bony expansion of the pyriform aperture was performed through an upper buccal sulcus incision.^{1,3} A gentle subperiosteal dissection was used to define the bony nasal inlet, which is usually visibly narrowed and medially located (Fig. 2). A 2-mm diamond burr was then used to widen the aperture by removing a strip of bone from the inferior inlet along the nasal floor to the lateral process of the maxilla (Fig. 3). Dissection is kept anterior to the inferior turbinate to avoid damage to the nasolacrimal duct, and caution is taken to prevent damage to the nasal mucosa and tooth bud prominences. Soft Silastic (Dow Corning, Midland, Mich.) nasal stents were used postoperatively and sutured to the columella (Fig. 4). These maintain airway patency during the period of postoperative edema and allow for nasal irrigation and suctioning. All patients were observed for a 24- to 48-hour period in the intensive care unit to ensure a patent airway. Parents were instructed on suctioning the stents before discharge. Nasal stents were removed in 5 to 7 days, depending on the severity of the stenotic segment. These stents were left in longer and extended further back into the nasopharynx when a choanal atresia repair was also performed. Vasoconstrictive nasal drops were alternated with normal saline drops for the first 5 days after stent removal and then discontinued. A first-generation cephalosporin and acetaminophen for pain was prescribed for the first week after surgery.

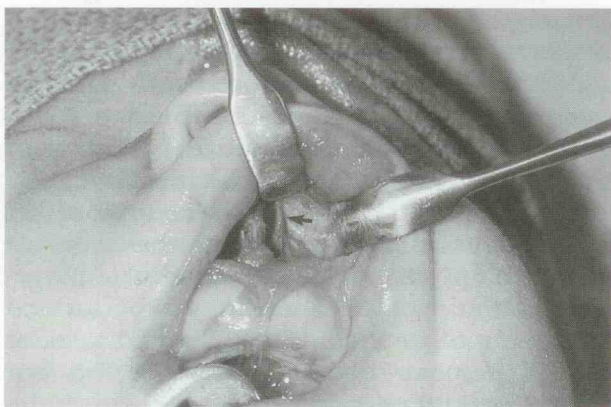


FIG. 2. Intraoperative view of the pyriform aperture by a sublabial approach. Note the narrowing of the pyriform aperture by bony overgrowth of the nasal process of the maxilla (black arrow).

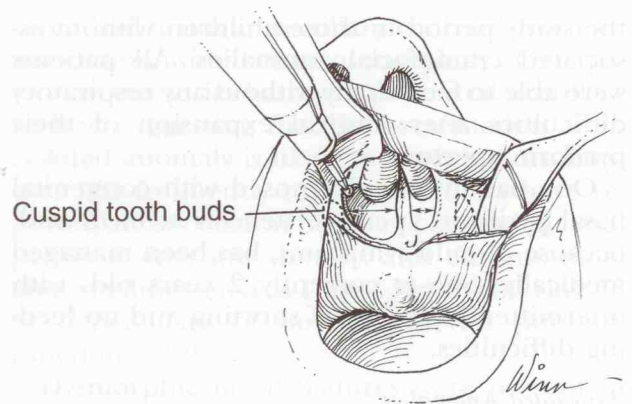


FIG. 3. Artist's rendition of the operative approach to the anterior nasal inlet, showing widening of the right pyriform aperture with a diamond burr. The left aperture is still stenosed. Note the close proximity of the tooth buds to the lateral nasal wall.

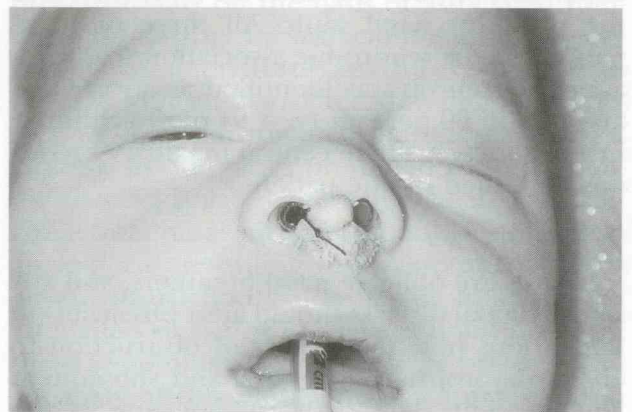


FIG. 4. Postoperative facial photograph demonstrating the soft nasal stents used to maintain nasal airway patency during the early recovery period.

RESULTS

The 14 patients who underwent surgical enlargement of the pyriform aperture have all been doing well, without any clinical evidence of restenosis, after a mean follow-up of 2.4 years (range, 1 month to 5 years). There were no reported complications, infections, airway difficulties, or readmissions. One patient had persistent symptoms of nasal airway obstruction in the early postoperative period and required a re-enlargement of her pyriform aperture. At long-term follow-up, all patients were able to breathe through their nose without any difficulty. Eight children were beyond the age of primary dentition, and except for the one child with a single central maxillary incisor, no disruption in dental eruption was evident. There were no gross disturbances in facial growth noted on physical examination during

the study period in those children without associated craniofacial anomalies. All patients were able to feed orally without any respiratory difficulties after surgical expansion of their pyriform aperture.

One patient was diagnosed with congenital nasal pyriform aperture stenosis at birth and, because of mild symptoms, has been managed medically. She is currently 2 years old, with intermittent episodes of snorting and no feeding difficulties.

Associated Anomalies

Associated craniofacial abnormalities were identified in 40 percent ($n = 6$) of the children in this series. Three patients in the series had pyriform stenosis and choanal atresia requiring expansion of both the anterior bony inlet and the posterior nasal vault. All three of these patients had a syndromic association. Pyriform aperture stenosis was identified as an isolated anomaly in 60 percent ($n = 9$) of the children in this series. A single central maxillary incisor was identified in one patient.

DISCUSSION

Infants are obligate nasal breathers, and any signs of nasal distress should alert physicians to the various potential causes of obstruction to ensure appropriate diagnosis and subsequent management. The pyriform aperture is the most anterior bony nasal opening, and stenosis in this region can be either traumatic or developmental in origin. Congenital nasal pyriform aperture stenosis is a rare midface anomaly and should always be considered in the differential diagnosis of infants with nasal airway obstruction.^{1,3-5} Approximately 30 cases of this anomaly have been described in the literature in the form of case reports and small series. We have presented our experience with 15 children diagnosed with congenital pyriform aperture stenosis, making it the largest series to date. The true incidence of this anomaly is unknown because of the varying degrees of stenosis and clinical presentation. Minor amounts of bony inlet stenosis may occur without severe nasal airway compromise and, subsequently, would not come to medical attention.

Brown et al.³ first described congenital nasal pyriform aperture stenosis in newborns. The exact cause still remains essentially unknown. Embryologically, the pyriform aperture is bounded superiorly by the nasal bones, inferiorly by the junction of the horizontal processes

of the maxilla, and laterally by the nasal process of the maxilla. Stenosis is thought to occur around the fourth month of fetal development because of an overgrowth of the ossification at the nasal process of the maxilla.³ This produces symptoms of functional airway obstruction in the newborn, often confused with the more common choanal atresia. Choanal atresia is a congenital narrowing or blocking of the posterior nasal airway by membranous or bony tissue. Although the level of obstruction in pyriform stenosis is at the anterior bony inlet, the symptomatic complex is essentially identical in these two conditions. Accurate early differentiation is important and will determine the appropriate management. The symptom complex in congenital nasal pyriform aperture stenosis can be varied, as can the timing of presentation. It usually occurs shortly after delivery, although it can manifest itself clinically during childhood with the onset of an infection of the upper respiratory tract. Cyclical cyanosis more pronounced while feeding is the most common early presentation. Other manifestations of obstruction include inspiratory stridor, sternal retractions, and poor feeding as a result of airway compromise. Frequent episodes of oxygen desaturation are common, with hypoxemia, hypercarbia, and acidosis all being possible. The diagnosis is most accurately confirmed by nasal endoscopy or computerized axial tomographic evaluation of the nasal and maxillary region. A radiographically measured pyriform aperture width of less than 11 mm per side in a full-term infant is considered to be diagnostic.⁶

Once the diagnosis has been confirmed, management is then dictated by the degree of stenosis, the symptom complex, and the overall prognosis of the infant. Milder cases can initially be managed conservatively with nasal decongestants and humidification. Surgical intervention is usually the definitive treatment in children with congenital nasal pyriform aperture stenosis who continue to be symptomatic. Early diagnosis and appropriate management is important. In our series, surgical enlargement of the pyriform aperture was performed 43 percent of the time within the first week of life, 57 percent of the time within the first month, and 86 percent of the time within the first year. Surgical enlargement of the pyriform aperture through a sublabial approach was initially advocated by Brown et al.³ and has been shown to be safe and effective. This technique

