

Reprinted from:

Rob & Smith's
Operative Surgery

Pediatric Surgery

Edited by

Lewis Spitz PhD, FRCS, FRCS(Ed), FAAP(Hon)

Nuffield Professor of Paediatric Surgery, Institute of Child Health, University of London, and
Consultant Paediatric Surgeon, Great Ormond Street Hospital for Children, London, UK

Arnold G. Coran MD

Professor of Surgery and Head of the Section of Pediatric Surgery, University of Michigan Medical
School, and Surgeon-in-Chief, C.S. Mott Children's Hospital, Ann Arbor, Michigan, USA

Fifth Edition

Protruding ears by S R Cohen and F D Burstein



CHAPMAN & HALL MEDICAL

London · Glasgow · Weinheim · New York · Tokyo · Melbourne · Madras

Published by Chapman & Hall, 2-6 Boundary Row, London SE1 8HN, UK

Chapman & Hall, 2-6 Boundary Row, London SE1 8HN, UK

Blackie Academic & Professional, Wester Cleddens Road,
Bishopbriggs, Glasgow G64 2NZ, UK

Chapman & Hall GmbH, Pappelallee 3,
69469 Weinheim, Germany

Chapman & Hall USA, One Penn Plaza, 41st Floor,
New York, NY 10119, USA

Chapman & Hall Japan, ITP-Japan, Kyowa Building, 3F, 2-2-1 Hirakawacho,
Chiyoda-ku, Tokyo 102, Japan

Chapman & Hall Australia, Thomas Nelson Australia,
102 Dodds Street, South Melbourne, Victoria 3205, Australia

Chapman & Hall India, R. Seshadri, 32 Second Main Road, CIT East,
Madras 600 035, India

© 1995 Chapman & Hall

Typeset in 10/11 Garamond ITC by Genesis Typesetting, Laser Quay, Rochester, Kent

Printed in Great Britain by Hartnolls, Bodmin, Cornwall

ISBN 0 412 59110 3

Apart from any fair dealing for the purposes of research or private study, or criticism or review, as permitted under the UK Copyright Designs and Patents Act, 1988, this publication may not be reproduced, stored, or transmitted, in any form or by any means, without the prior permission in writing of the publishers, or in the case of reprographic reproduction only in accordance with the terms of the licences issued by the Copyright Licensing Agency in the UK, or in accordance with the terms of licences issued by the appropriate Reproduction Rights Organization outside the UK. Enquiries concerning reproduction outside the terms stated here should be sent to the publishers at the London address printed on this page.

The publisher makes no representation, express or implied, with regard to the accuracy of the information contained in this book and cannot accept any legal responsibility or liability for any errors or omissions that may be made.

A catalogue record for this book is available from the British Library

Library of Congress Catalog Card Number: 94-68719

Protruding ears

Steven R. Cohen MD

Co-Director, Center for Craniofacial Disorders, Scottish Rite Children's Hospital, Atlanta, Georgia, USA

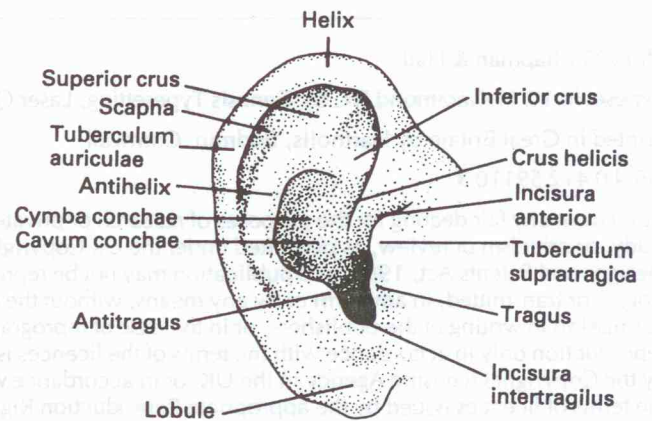
F. D. Burstein MD

Co-Director, Center for Craniofacial Disorders, Scottish Rite Children's Hospital, Atlanta, Georgia, USA

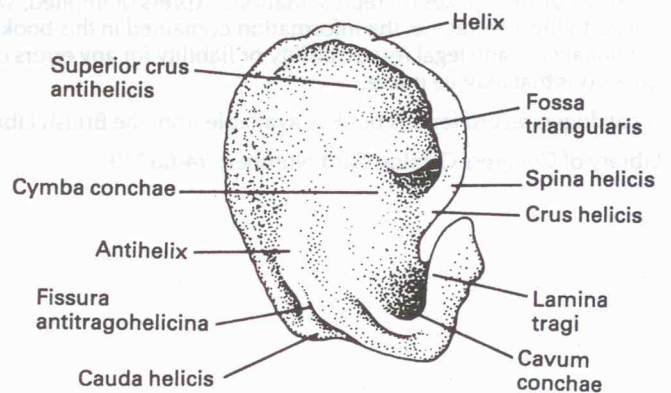
Principles and justification

Anatomy of the external ear

1a, b The auricle is approximately 6 cm long in the adult. It lies between horizontal lines at the upper rim of the orbit and nasal spine and protrudes at about 30° from the skull¹. The gap between the upper part of the helix and the skull is usually less than 2 cm. The cartilage has depressions and ridges that are easily seen in the overlying skin. The auricularis posterior is the thickest of three extrinsic muscles to the ear. It originates on the base of the mastoid and inserts onto the ponticulus, which is opposite the concha.

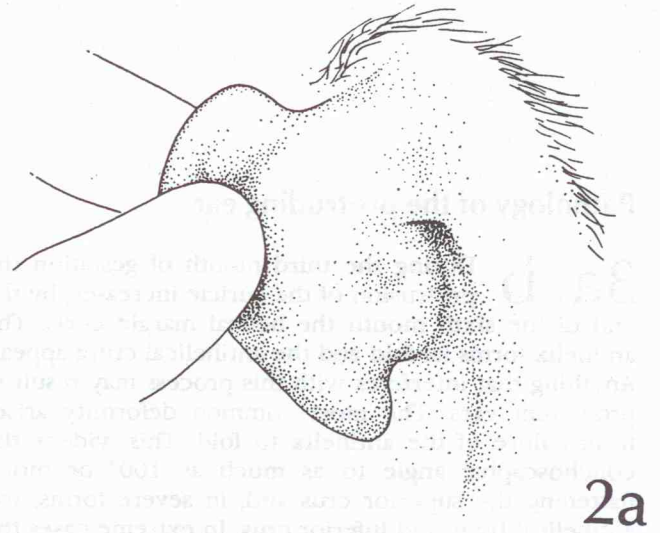


1a

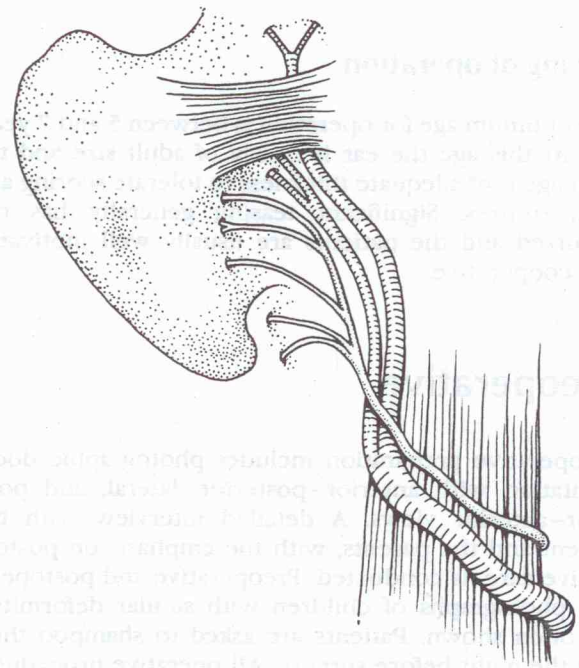


1b

2a, b Clinically, the auricularis posterior is demonstrated by pulling the ear forward. It is innervated by the posterior auricular branch of the facial nerve. The posterior auricular veins travel just deep to the great auricular nerve and are commonly encountered during deep dissection to expose the concha. To avoid bleeding the auricularis posterior muscle is best divided with electrocautery.



2a



2b

Pathology of the protruding ear

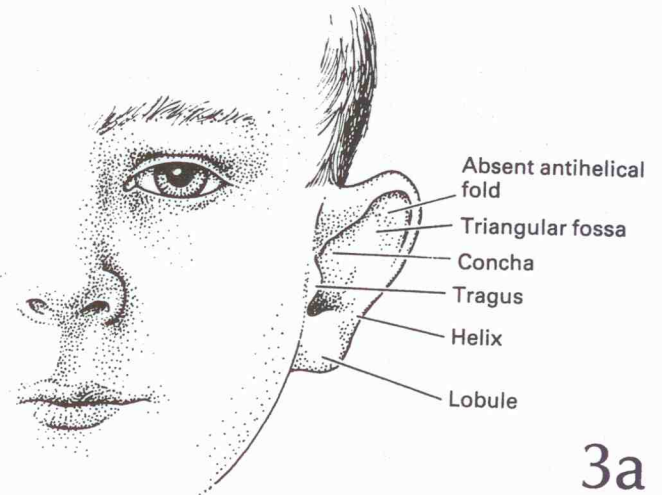
3a, b During the third month of gestation the protrusion of the auricle increases; by the end of the sixth month the helical margin curls. The antihelix forms its fold and the antihelical crura appear. Anything that interferes with this process may result in prominent ears. The most common deformity arises from failure of the antihelix to fold. This widens the conchoscaphal angle to as much as 100° or more, flattening the superior crus and, in severe forms, the antihelical body and inferior crus. In extreme cases the helical rim may be absent, producing a flat, shell-like ear. The normal ear has a conchoscaphal angle of 90° or less, while the prominent ear has more obtuse angulation. Abnormalities are often bilateral and frequently present with variable degrees of symmetry.

Timing of operation

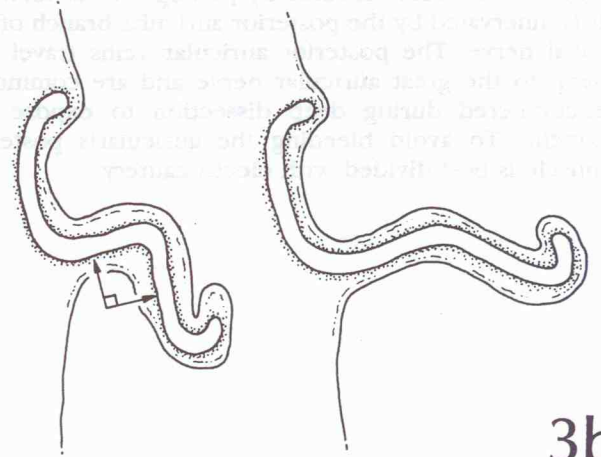
The optimum age for operation is between 5 and 7 years old. At this age the ear is nearly of adult size and the cartilage is of adequate thickness to tolerate scoring and hold sutures. Significant teasing generally has not occurred and the patients are usually well motivated and cooperative.

Preoperative

Preoperative preparation includes photographic documentation with anterior–posterior, lateral, and posterior–anterior views. A detailed interview with the patient and the parents, with the emphasis on postoperative care, is conducted. Preoperative and postoperative photographs of children with similar deformities are often shown. Patients are asked to shampoo their hair the night before surgery. All operative procedures are done on an outpatient basis under general anesthesia. Intravenous antibiotics are routinely given before skin incision.



3a



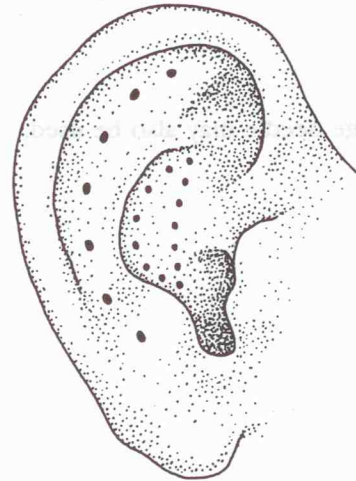
3b

Operations

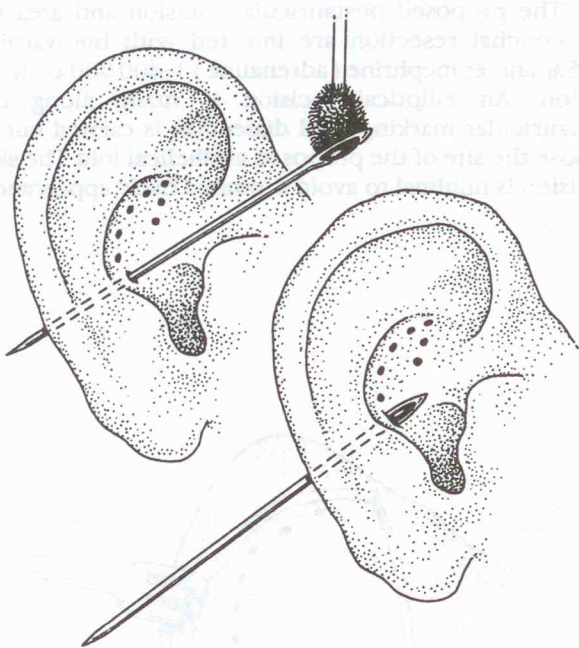
MUSTARDÉ'S PROCEDURE

Correction of the ear with either normal or absent antihelical fold is known as Mustardé's procedure².

4 The desired location of the antihelical fold and, if indicated, the amount of conchal resection, are marked using methylene blue.



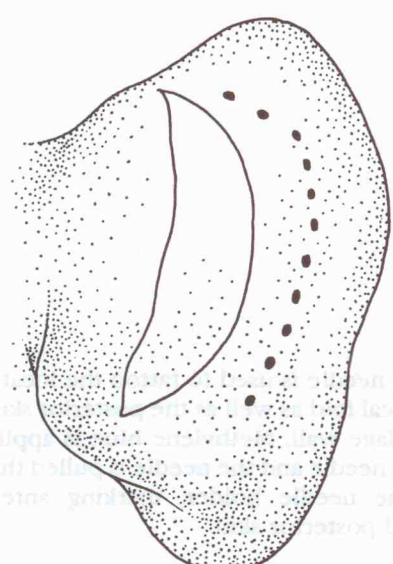
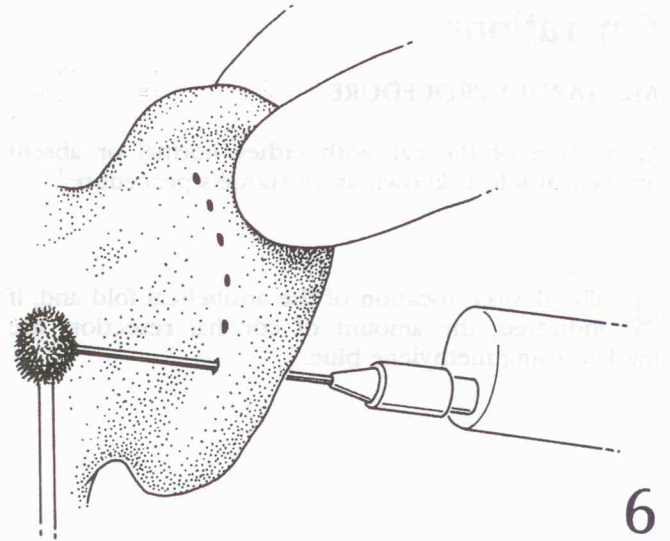
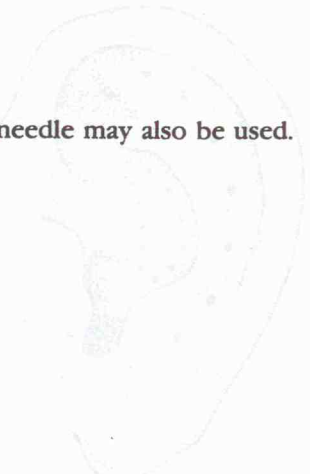
4



5

5 A Keith needle is used to tattoo the location of the antihelical fold as well as the posterior skin incision on the cartilage wall. Methylene blue is applied to the eyelet of the needle and the needle is pulled through the ear with the needle holder, marking anterior skin, cartilage and posterior skin.

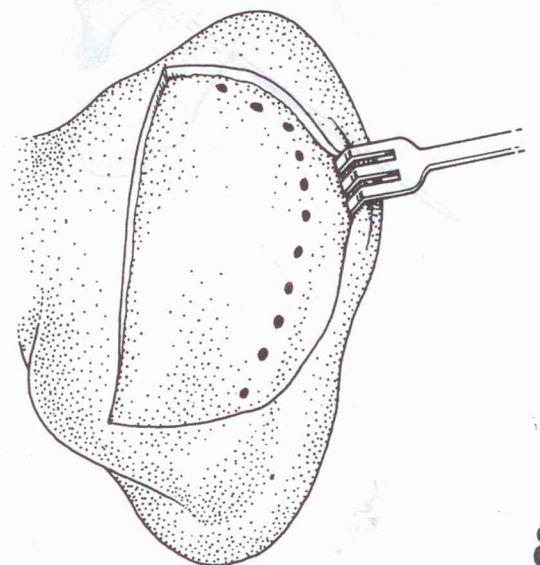
6 A 22 gauge needle may also be used.



7 The proposed postauricular incision and area for conchal resection are injected with bupivacaine 0.25% and epinephrine (adrenaline) 1:400 000 concentration. An elliptical incision is made along the postauricular markings and dissection is carried out to expose the site of the proposed antihelical fold. The skin excision is minimal to avoid a 'pinned back' appearance.

7

8 The dissection is carried out directly over the cartilage with an Iris scissor, or in the subcutaneous plane using electrocautery. The previously placed methylene blue tattoos along the line of the antihelical fold are directly visualized.



8

