

The Use of Granular Hydroxyapatite in Secondary Orbitocranial Reconstruction

F. BURSTEIN, S. COHEN, R. HUDGINS* and W. BOYDSTON*

Center for Craniofacial Disorders,

**Department of Neurosurgery*

Scottish Rite Children's Hospital, Atlanta, Georgia, USA

SUMMARY

There has been intense interest in materials that can be used as bone substitutes in craniofacial surgery. Hydroxyapatite is one such material that combines osseointegration with maintenance of implant volume and excellent durability. We present our experience in 16 patients ranging in age from 3 to 22 years (mean 8 years), who underwent secondary orbitocranial reconstruction utilizing porous granular hydroxyapatite (P.H.A.).

INTRODUCTION

There has been intense interest in biomaterials that can be used as bone substitutes in craniofacial and maxillofacial surgical applications. Certain mechanical and biologic properties are highly desirable but relatively difficult to obtain. These properties include long term tissue tolerance, mechanical strength, torque resistance, ease of application, and stability over time: 1) Hydroxyapatite, H.A., is a synthetic bone graft substitute made by conversion of the calcium carbonate exoskeleton of sea coral, which is available in block and granular forms; 2) Its porous structure behaves as a scaffold and allows ingrowth of native surrounding osseous tissues, with bony union seen as early as 90 days after implantation; 3) The use of block H.A. to span osteotomy gaps in maxillofacial surgery has been successful despite its fragility when submitted to rotatory stresses; and 4) Block H.A. is difficult to shape and fixate due to its inherent fragility, particularly after it ab-

sorbs moisture, making it less than ideal for filling of contour defects. The edges of the blocks often show below relatively thin soft tissue covering such as the forehead and periorbital regions. Porous Granular Hydroxyapatite, P.H.A., although lacking in compressive strength, is ideal for filling contour defects in the upper facial skeleton.

MATERIALS AND METHODS

Sixteen patients ranging in age from 3 to 22 years (mean 8 years) underwent P.H.A. reconstruction of a variety of frontal bone, temporal and upper orbital bony contour defects. These included five patients with fronto-orbital trauma, nine who had frontal orbital advancements for craniosynostosis and two who were post frontal bone ablation and reconstruction for tumors. All patients were at least one year post initial reconstruction at the time of their secondary surgery.

Follow up was from 6-72 months (mean 30 months). P.H.A. (granule size 425-1000 microns) was mixed in a ratio of 1.0 cc P.H.A. to 0.50 cc of the patient's blood and 0.50 cc of microfibrillar collagen to form a dense paste of adherent P.H.A. The bony defects were all approached through a bicoronal incision, taking great care to stay in a supraperiosteal plane. The periosteum was raised as an anteriorly based vascularized flap. In cases where the temporal areas needed to be addressed, the temporalis muscle was raised in the deep subperiosteal plane. Protuberant hardware was removed, and all bony peaks were burred down prior to filling of the defects with the P.H.A. paste. The periosteal flaps were then sutured at the borders of the bony defects in order to create a sealed pocket for the P.H.A. paste (Fig. 1-3). A neurosurgical type head dressing was kept on for five days postoperatively, followed by a soft headband for an additional two weeks. All patients received five days of oral antibiotics.

RESULTS

There were no major surgical complications. One patient had a persistent temporal fossa infection after placement of P.H.A., with granule extrusion through the coronal wound, necessitating debridement of all P.H.A. The remaining 15 patients had no postoperative problems with

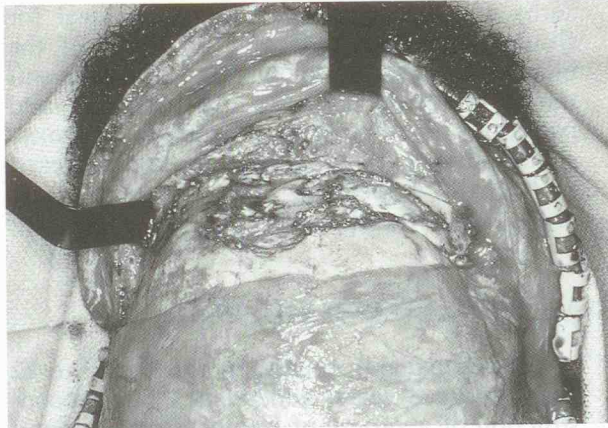


Fig. 1: Intraoperative photograph taken 18 months after initial operation for severe fronto-orbital trauma. Note bony irregularities due to resorption despite rigid fixation.

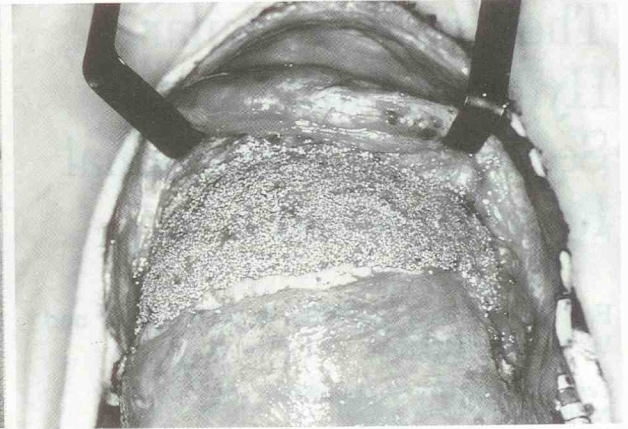


Fig. 2: Intraoperative photograph of patient in Fig. 1 with P.H.A. paste applied to contour defects.

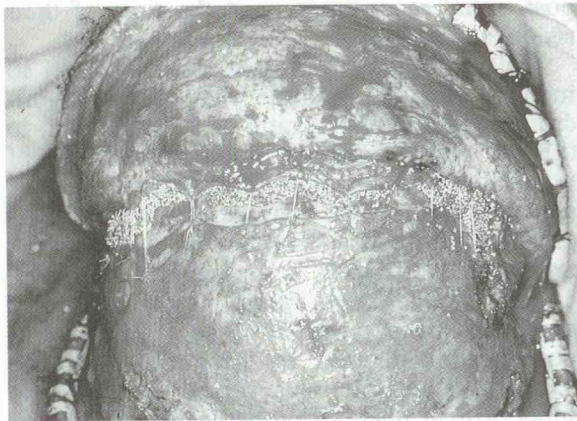

Fig. 3: Intraoperative photograph of patient in Fig. 1 with vascularized periosteal flaps closed over P.H.A. paste.

good contours of the P.H.A.-filled defects, maintenance of implant volume, and nonvisible interfaces between P.H.A.-grafted areas and the native bone (Fig. 1-3). We were able to examine the P.H.A.-grafted areas in three patients who underwent other procedures 9-18 months after P.H.A. placement. In all three cases there were visible bony ingrowth into the consolidated P.H.A. and bleeding from the P.H.A. surface.

DISCUSSION

Contour defects in the orbitocranial region

after surgery for trauma, tumor, or synostosis are relatively common due to bone resorption [5, 6]. In the past we attempted to bone graft these contour defects but were disappointed by minor irregularities that became visible over time. Next we attempted to use block H.A. but experienced problems with fixation, palpable and visible edges, and intraoperative shattering of the blocks. P.H.A. overcomes many of these problems and offers an alternative to conventional autographs while maintaining its volume and becoming osseointegrated [7]. The maintenance of viable periosteum is essential since it provides a source of osteogenic cells to populate the P.H.A. surface [8]. Careful closure of the periosteal pocket is important to prevent surface extrusion and possible bacterial contamination of the P.H.A., as occurred in one of our patients.

REFERENCES

- [1] BAL M.B., REDDI A.H.: *Bone grafts and bone induction substitutes*. "Clin. Plast. Surg.", 21(4): 525, 1994.
- [2] SARTORIS D.J., GERSUIN D.H., AKESON W.H., ET AL.: *Coralline hydroxyapatite bone graft substitutes: preliminary reports of radiographic evaluation*. "Radiology", 159: 133, 1986.
- [3] SARTORIS D.J., HOLMES R.E., BUCHOLZ R.W., ET AL.: *Coralline hydroxyapatite bone graft substitutes in a canine diaphyseal defect model. Radiographic-histometric correlation*. "Invest. Radiol.", 22: 590, 1987.
- [4] ROSEN H.M.: *Porous block hydroxyapatite as an interposition graft substitute in orthognathic sur-*

- gery. "Plast. Reconst. Surg.", 985, 1989.
5. WOLFE S.A.: *Application of craniofacial surgical precepts in orbital reconstruction following trauma and tumor removal.* "J. Maxillofac. Surg." 10: 212, 1982.
 6. MCCARTHY J.G., EPSTEIN F.J., WOOD-SMITH D.: *Cranio-synostosis.* In J.G. MCCARTHY (Ed.), *Plastic Surgery*, Vol 4. Philadelphia: Saunders, 1990, pp 3013-3053.
 7. BYRD H.S., HOBAR C.P., SHEWMAKE K.: *Augmentation of the craniofacial skeleton with porous hydroxyapatite granules.* "Plast. Reconst. Surg.", 91: 15, 1993.
 8. BEGLEY C.T., DOHERTY M.J., HANKEY D.P., ET AL.: *The culture of human osteoblasts upon bone graft substitutes.* "Bone", 14: 661, 1993.